

Death Following Atypical Compression of the Neck

Nunzio Di Nunno, MD, Michele Vacca, MD, Fulvio Costantinides, MD, and Cosimo Di Nunno, MD

Abstract: The authors present 3 cases of asphyxia caused by atypical compression of the neck by the metal bed bars fitted at the sides of the bed to prevent falling out. These occurred in 3 elderly women living in nursing homes, confined to bed by severe neuropsychiatric disturbances. In all 3 cases, the minor nature of the skin lesions and absence of blood infiltrations in the anatomic structures of the neck had made it difficult to diagnose the cause of death. Inspection of the rest homes, together with the autopsy findings (acute pulmonary emphysema, conjunctival petechiae, and dark, fluid blood), enabled identification of asphyxia as the cause of death and its causal agent as the bed bars.

Key Words: atypical compression of the neck, nursing home, bed bars, vagal reflex

(*Am J Forensic Med Pathol* 2003;24: 364–368)

In the last 10 years, progressive aging of the population has resulted in growing popularity of health facilities providing geriatric services. The severe chronic diseases that can affect the elderly often confine them to bed for long periods. We describe 3 unusual cases of accidental death caused by asphyxia secondary to atypical compression of the neck that occurred in Trieste.

Death by asphyxia can present in various different ways. It is usually determined by typical actions imputable to the asphyxial agent, classically classified as strangling, throttling, hanging, and drowning. All these are due to external compression exerted on the neck. Cases of violent mechanical asphyxia occurring accidentally in hospital facilities and nursing homes for the elderly have also been described in the

literature.^{1–4} These studies show that most deaths occurring in such facilities tend to be rather cursorily dismissed as having been caused simply by the physical conditions and severe diseases from which the elderly patients suffered.³ Cases of atypical compression differ from the classic pictures of death by asphyxia because, although they are due to the same pathogenetic mechanisms, they do not leave strong signs of skin lesions, visible on external examination as finger-shaped ecchymoses and nail marks due to throttling, or a soft or hard ridge running round the neck due to strangling or hanging.

Various atypical forms have been described, caused by rods or sticks used to compress the neck anteroposteriorly, by wooden rods with cords or screws attached to their extremities used in garroting, by violent pulling of the neck backwards in a pincer movement between the forearm and arm in mugging, or by compression of the victim's neck by the aggressor's knee or foot.⁵ There have also been cases of "passive strangling" in which the subject loses consciousness, and in falling, the neck presses against an object that compresses the airway. In this case, it is the weight of the body that causes death.^{6–7} So-called passive strangling and accidental forms of asphyxia due to direct compression on the neck by sliding doors or automatic windows are classified as violent mechanical asphyxia.

In asphyxial syndromes, it is even possible for all the findings to be negative in particular cases when death is due to direct neurogenic action (compression of the neck) at the cardiac level and the time is too short for petechiae and other signs to form. In any case, the typical signs may not all be present or evident due to biologic variability and individual reactions. In fact, there is some ability to resist temporary suspension of breathing activities that varies according to factors of a physiological (physical constitution, age, physical fitness), pathologic (respiratory, blood, cardiovascular disease), and environmental (temperature, humidity) nature.

CASE 1

An 81-year-old woman living in a nursing home for the elderly was found deceased at 5:45 AM by a nurse working in the facility (Fig. 1, 2, 3). The head was positioned between the edge of the mattress and the lower metal bed bar. The body was moved by the nurse while attempting resuscitation.

Manuscript received March 14, 2003; May 29, 2003.

From the Department of Internal and Public Medicine, Section of Forensic Medicine, University of Bari (N.D.N., M.V., C.D.N.), and Department of Clinical Sciences and Sciences of Public Medicine, University of Trieste (F.C.).

Corresponding Author: Nunzio Di Nunno M.D., Section of Forensic Medicine, Department of Internal Medicine and Public Medicine, University of Bari, Piazza G. Cesare n. 11, 70124 Bari, ITALY. E-mail: forem@medicinalegale.uniba.it.

Copyright © 2003 by Lippincott Williams & Wilkins
0195-7910/03/2404-0364

DOI: 10.1097/01.paf.0000098506.31964.f5

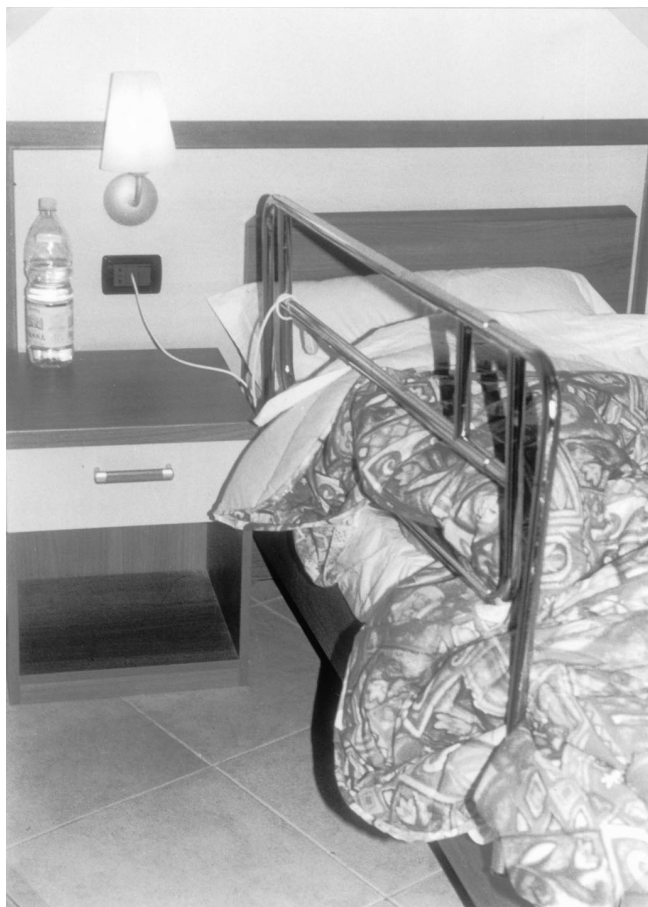

FIGURE 1. The bed bars fitted at the sides of the bed.

The patient was affected by Alzheimer’s disease, and about 3 months before, she had suffered an epileptic crisis. External examination showed minute abrasions of the external angle of



FIGURE 2. The head of the first victim positioned between the edge of the mattress and the lower bed bar.

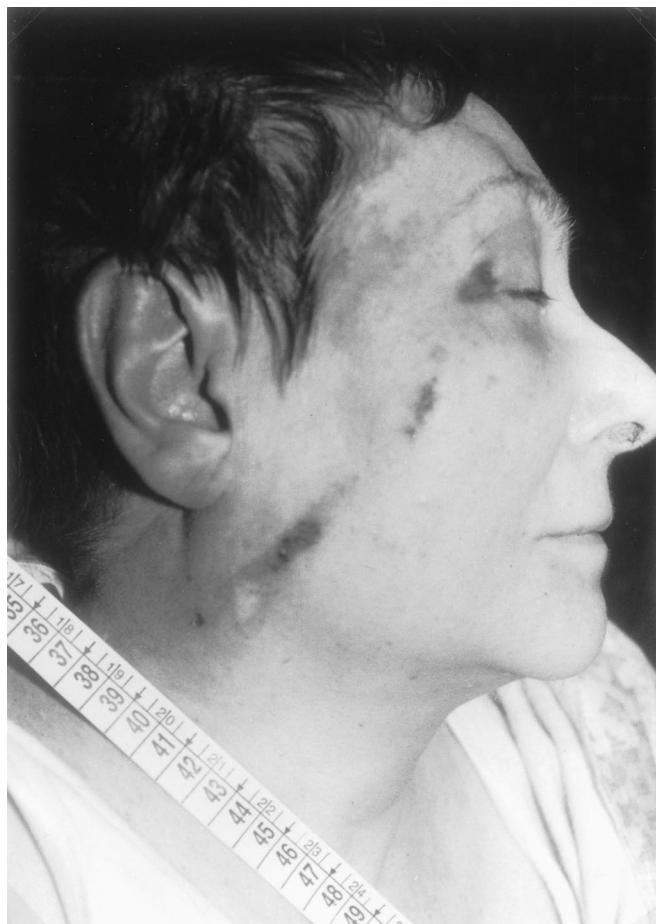

FIGURE 3. The abraded area of ecchymoses, slightly depressed with respect to the surrounding skin, appearing as a track.

the right eye. Between the external angle of the right eye and the base of the neck, in the right laterocervical site, an abraded area of ecchymoses, 19 cm long and 1 cm wide, became more and more evident with the passing of time. The slightly depressed appearance of this area, resembling a track, seemed to indicate that it had been produced by compression against a curved surface. The autopsy did not reveal hemorrhagic infiltrate at the level of the oral cavity, neck, tongue, or vascular-nerve fascia of the neck, but dark, fluid venous blood was present. The lungs were dull red, and when pressed, a pale fluid exuded. Histology showed only diffuse alveolar rupture fluid (indicating acute pulmonary emphysema).

CASE 2

An 81-year-old woman living in a nursing home for the elderly, affected by neuropsychiatric disturbances, was found at 6:20 AM by a nurse; the body was lying supine, reversed with the head at the foot of the bed, and caught between the middle and the lower bed bar (Fig. 4). It was moved while attempting resuscitation. On external examination, the ca-

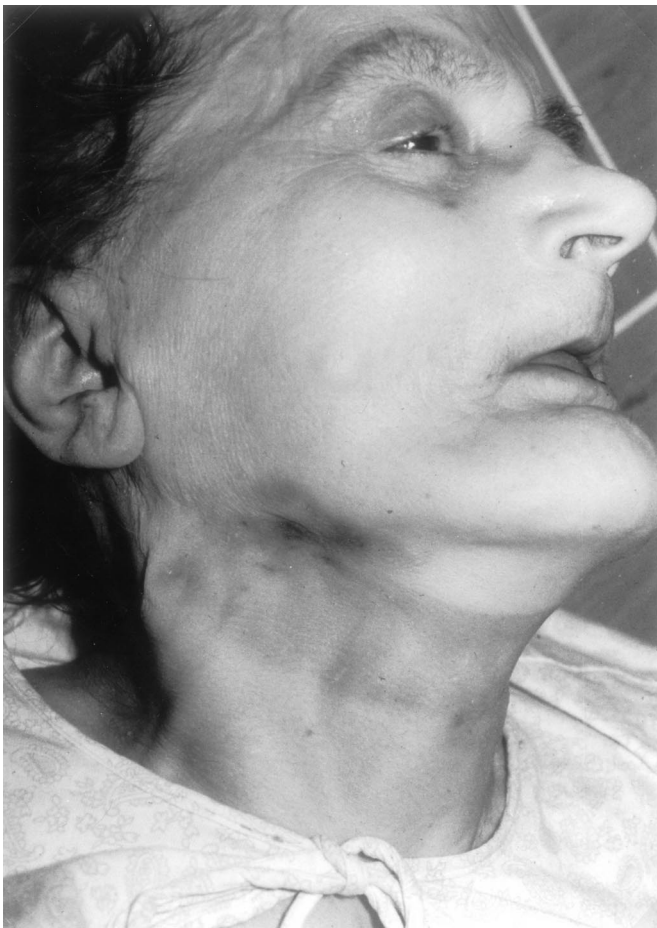

FIGURE 4. The abraded area of ecchymoses present at the level of the right mandibular angle with a skin depression at the base of the neck of the second victim.

daver presented hemorrhagic petechiae and conjunctival bleeding, together with diffuse bleeding areas at the level of the mucosa of the upper lip. There was a depressed, yellowish band with a purplish halo 29 cm long and 2 cm wide running along the base of the neck from the right laterocervical region up to the contralateral anterior armpit. The size of the band corresponded to that of the surface of 1 of the tubular bed bars (having a diameter of 22 mm and circumference of 75 mm) serving to prevent patients from falling out of bed. Autopsy did not show lesions of the tongue, larynx, hyoid bone, musculature, or cervical rachis. The left hemithorax presented hemorrhagic infiltration of the muscle tissues underlying the band of skin compression described above. The blood was dark and fluid. Both lungs were compact and increased in weight; when dissected they appeared congested, and finger pressure caused exudation of a fine, foamy liquid tinged with blood. Histology showed diffuse rupture of the alveolar septi (indicating acute pulmonary emphysema).




FIGURE 5. The position of the third victim.

CASE 3

A 68-year-old woman living in a nursing home for the elderly, affected by Parkinson's disease (third-fourth stage) was found dead at 11:50 PM by the night nurse (Fig. 5, 6, 7). She had been found kneeling with her head stuck between the bed bars of the bed. While attempting resuscitation, the nurse had succeeded in extracting the head and laying the body flat on the floor. External examination showed a transverse, bluish band running from the base towards the top of the neck, 35 mm wide (the same size as the circumference of the railing). There was also a small abraded area of ecchymoses at the level of the right mandibular angle. Autopsy did not show lesions of the tongue, larynx, hyoid bone, muscles, or cervical rachis, although dark, fluid venous blood was present. The lungs were dark red, and a pale liquid exuded

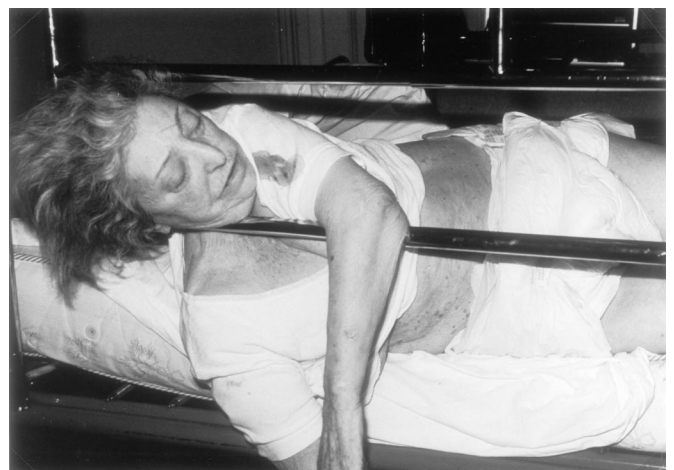

FIGURE 6. The woman's head, positioned between the upper and lower bed bars.

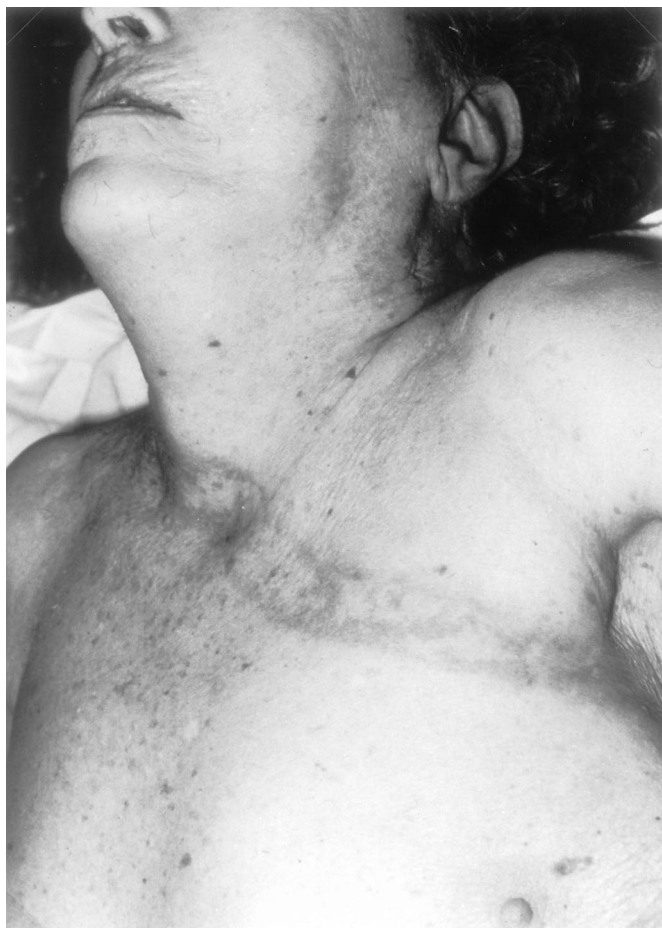

FIGURE 7. The skin lesion produced by compression of the neck by the bed bar.

when they were pressed. Histology showed only diffuse alveolar rupture (indicating acute pulmonary emphysema).

DISCUSSION

The 3 cases that came to our observation were elderly women living in 3 different nursing homes for the elderly, confined to bed by severe neuropsychiatric disease, whose beds were fitted with bed bars of the same type in each case to prevent them from falling out.

These extensible bed bars are made of chrome metal telescopic tubes fixed parallel at 15 cm distance one from the other. Some models can be extended horizontally, as shown in the photos.

The 3 cases featured similar characteristics. In all cases, the autopsy and histologic findings were aspecific, and no eye witnesses had been present at the time of decease.

All the evidence available, after excluding any responsibility of third parties, together with reconstruction of the position of the bodies at the time of death, before they had been moved during resuscitation attempts, led to the conclu-

sion that the 3 women must have met their death due to conscious or unconscious nocturnal movements (in view of the severe psychiatric disturbances they suffered from). These must have resulted in the head slipping between the edge of the mattress and the lower bed bar (case 1), or between 2 bed bars (cases 2 and 3) and causing fatal compression of the neck.

Compression of the neck region can determine asphyxia due either to mechanical pressure on the larynx resulting in occlusion of the airways or to stimulation of the nerve centers (carotid sinus, carotid glomus), leading to death by mechanical reflex (neurogenic inhibition), leaving no apparent signs of asphyxia. Pressure on the baroreceptors present at the level of the carotid sinus, carotid sheaths, and carotid glomi can bring on bradycardia or cardiac arrest. This is caused by an arc reflex in which the afferent sensitive nerve impulse stems from nerve terminals at the level of the carotid complex but not from the vagal trunk itself. The impulse reaches the brain through the glossopharyngeal nerves at the tenth cranial nerve nucleus in the brain stem and returns via the vagus (efferent route) to the heart and other organs. The arc reflex occurs in the parasympathetic part of the autonomous nervous system and is independent of the main sensitive and motor nerves.

The vagal reflex, which can be triggered even by very minor trauma, has important implications as regards compression and trauma of the neck. It is still not known whether the reflex can bring on immediate cardiac arrest, whether there is a period of gradual slowing of the cardiac rhythm with negligible cardiac output, or whether arrhythmia, such as ventricular fibrillation, precedes the final arrest. Each of these combinations may occur, and it is known to be possible for any external signs to be absent or only very minor.⁸

Moreover, it is quite possible that death may be due to the combined effect of a classic asphyxial mechanism and the reflex mechanism. Although the first stage of pressure on the neck must last a sufficient time (probably at least 15–30 seconds) for asphyxial signs to appear, a change in compression even due to a slight alteration in the position of the victim, for instance (as could have occurred in our case 1, the weight moving slightly away from the edge of the mattress causing tightening against the neck) could cause external stimulation of the nerve terminals, leading to cardiac arrest. The morphologic picture may therefore vary widely, according to when classic asphyxia with its relative signs is interrupted in a given moment of its evolution.

We must also remember that our victims were all elderly, so that the physiological senile visceral involution process would have made them much more susceptible to acute hypoxia. This would explain why there were no marked subcutaneous signs at autopsy, despite other typical signs (edema and pulmonary emphysema; dark, fluid blood).

Moreover, in our cases, the absence of lesions of the deep structures of the neck must be attributed to the curved, smooth surface of the bed rails that compressed the respiratory tract and stimulated the nerve impulses without damaging the subcutaneous tissues, cartilage, or bone. Thus, the diagnosis of acute asphyxia due to atypical compression of the neck was made as a result of interpretation of aspecific histologic signs such as rupture of the alveolar septi (due to acute pulmonary emphysema), together with other findings such as the presence of subcutaneous and subconjunctival petechiae. These were combined with the reconstruction of the circumstances in which the bodies were found and the information gained on inspection of the site and from the legal investigations of the police force.

It is clear that bed bars, commonly used in all public and private health facilities, can be extremely dangerous, especially in elderly patients in poor psychophysical conditions. This is because there is too large a space between the rails and between them and the edge of the mattress. The wide spaces make it relatively easy for patients to slip sideways and get their head stuck between the rails, with lethal consequences like those we describe.

Finally, we should emphasize that the nutritional conditions of the 3 women we observed were not particularly poor; on the contrary, 1 case featured mild obesity, so that

excessive thinness cannot be numbered among the factors favoring slipping between the mattress and lower bed bar or between 2 bed bars. In any case, since these 3 cases that occurred in Trieste were reported by the forensic expert to the competent authorities, we have noticed that many health facilities have started to adopt a different bed bar, no longer tubular bars (that may contribute to slipping) but rectangular bars fitted much closer together.

REFERENCES

1. Flobecker P, Ottosson J, Johansson L, et al. Accidental deaths from asphyxia: a 10-year retrospective study from Sweden. *Am J Forensic Med Pathol.* 1993;14:74–79.
2. Osculati A, Fassina G. Two cases of accidental asphyxia by neck compression between bed bars. *Am J Forensic Med Pathol.* 2000;21:217–219.
3. Corey TS, Weakley Jones B, Nichols GR II, et al. Unnatural deaths in nursing home patients. *J Forensic Sci.* 1993;37:222–227.
4. Sperry K, Smialek JE. The investigation of an unusual asphyxial death in hospital. *JAMA.* 1996;255:2472–2474.
5. Umani Ronchi G, Bolino G, Grande A, et al. Lesioni da mezzo asfissigeno. In: Umani Ronchi G, Bolino G, Grande A, et al, eds. *Patologia Forense.* Milano: Giuffrè Editore; 1994;495–576.
6. Madea B. Death in head-down position. *Forensic Sci Int.* 1993;61:119–132.
7. Bell M, Rao V, Wetli C, et al. Positional asphyxia in adults: a series of 30 cases from the Dade and Broward County Florida Medical Examiners Offices from 1982 to 1990. *Am J Forensic Med Pathol.* 1992;13:101–107.
8. Knight B. Fatal pressure on the neck. In: Knight B, ed. *Forensic Pathology.* New York, NY: Arnold; 1996;361–364.