

Circulation

JOURNAL OF THE AMERICAN HEART ASSOCIATION



Sudden Cardiac Arrest and Death Associated with Application of Shocks from a TASER Electronic Control Device

Douglas P. Zipes

Circulation published online April 30, 2012

Circulation is published by the American Heart Association, 7272 Greenville Avenue, Dallas, TX 75214
Copyright © 2012 American Heart Association. All rights reserved. Print ISSN: 0009-7322. Online ISSN:
1524-4539

The online version of this article, along with updated information and services, is located on
the World Wide Web at:

<http://circ.ahajournals.org/content/early/2012/04/20/CIRCULATIONAHA.112.097584>

Subscriptions: Information about subscribing to *Circulation* is online at
<http://circ.ahajournals.org/subscriptions/>

Permissions: Permissions & Rights Desk, Lippincott Williams & Wilkins, a division of Wolters Kluwer
Health, 351 West Camden Street, Baltimore, MD 21202-2436. Phone: 410-528-4050. Fax:
410-528-8550. E-mail:
journalpermissions@lww.com

Reprints: Information about reprints can be found online at
<http://www.lww.com/reprints>

**Sudden Cardiac Arrest and Death Associated with Application of Shocks
from a TASER Electronic Control Device**

Running title: *Zipes; Electronic control device induced cardiac arrest*

Douglas P. Zipes, MD



Krannert Institute of Cardiology, Indiana University School of Medicine, Indianapolis, IN

Circulation

Corresponding author:

Douglas P. Zipes, MD

Krannert Institute of Cardiology

Indiana University School of Medicine

1800 N. Capitol Ave.

Indianapolis, IN 46032

Tel: 317 962 0556

Fax 317 963 0568

E-mail: dzipes@iupui.edu

Journal Subject Codes: [5] Arrhythmias, clinical electrophysiology, drugs

Abstract:

Background - Rationale: The safety of electronic control devices (ECDs) has been questioned. The rationale for this submission was to analyze in detail cases of loss of consciousness associated with ECD deployment.

Methods and Results - Eight cases of TASER X26 ECD-induced loss of consciousness were studied. In each instance, when available, police, medical and emergency response records, ECD dataport interrogation, automated external defibrillator (AED) information, ECG strips, depositions, and autopsy results were analyzed. First recorded rhythms were ventricular tachycardia/fibrillation in six and asystole (after about 30 minutes of non-responsiveness) in one. An external defibrillator reported a “shockable rhythm” in one, but no recording was made. This report offers evidence regarding the mechanism by which an ECD can produce transthoracic stimulation resulting in cardiac electrical capture and ventricular arrhythmias leading to cardiac arrest.

Conclusions - ECD stimulation can cause cardiac electrical capture and provoke cardiac arrest due to ventricular tachycardia/ventricular fibrillation. After prolonged ventricular tachycardia/ventricular fibrillation without resuscitation, asystole develops.

Key words: cardiac arrest; sudden death; ventricular fibrillation; TASER; electronic control device

Introduction

Electronic control devices (ECDs), also referred to as conducted electrical weapons, are called “less lethal” or “non--lethal” weapons since their intent is to temporarily incapacitate, not to kill. The ECD manufactured by TASER International, Model X26, is the device most widely used by law enforcement, corrections, and military establishments worldwide. It is a handgun-shaped weapon that uses compressed nitrogen to shoot two 9- or 13-mm barbs from a cartridge into the clothes/skin of an individual. Wires connect the barbs through the cartridge to the gun through which is delivered an initial 50,000 volt shock, followed by 100 microsecond pulses at about 19 Hz (about 1140 times per minute), 2-4 amps, 100 microcoulombs charge per pulse, and approximately 1,200 volts (1). The standard 5-second-shock cycle can be halted earlier, repeated, or sustained longer by the user. If electrical current from both darts connect with the subject, pain and skeletal muscle contraction generally result in rapid incapacitation. The gun’s exposed electrodes can be pressed against the skin (“drive stun mode”) to cause pain without muscular contractions. ECDs are not considered firearms and therefore not regulated by the Bureau of Alcohol, Tobacco, Firearms, and Explosives.

The safety of ECDs has been questioned. Amnesty International documented 334 deaths that occurred after exposure to ECDs between 2001 and 2008 (2). To date, no peer-reviewed publication has definitely concluded that ECD shocks can precipitate ventricular fibrillation (VF) causing sudden cardiac arrest and death.

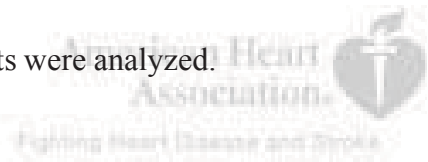
The purpose of this report is to present an analysis of sudden cardiac arrests and deaths during ECD exposure that occurred in 2006 (Case 1); in 2008 (Cases 2, 4, 5, 8) and 2009 Cases 3, 6, 7) and weigh the existing animal and clinical data to determine whether an ECD shock can cause cardiac electrical capture, and in so doing, provoke ventricular tachycardia (VT) and/or

VF.

Methods

The medical information used for this article was approved by the Institutional Review Board of the Indiana University School of Medicine. Written and informed consent was obtained from each person or an authorized representative.

The cases included have been studied as part of litigation related to administration of ECD shocks from the TASER X26 device. In each instance, when available, police, medical and emergency response records, X26 dataport interrogation, automated external defibrillator (AED) information, ECG strips, depositions, and autopsy results were analyzed.



Results

All individuals were 1) previously clinically healthy males, 2) received shocks from the TASER X26 ECD with one or both barbs in the anterior chest near or over the heart, and 3) developed loss of consciousness during or immediately after the ECD shock (table 1). First recorded rhythms were ventricular tachycardia/fibrillation in six and asystole (after about 30 minutes of non-responsiveness) in one (figure 1).

An external defibrillator reported a “shockable rhythm” in one, but no recording was made. Except for case 1, all died.

Discussion

New Observations

This report adds detailed observations on 8 new cases of sudden cardiac arrest/death associated

with ECD shocks to those already in the literature.

Published Case Reports

The first published report of sudden cardiac arrest after ECD discharge was a letter to the editor about a 14 year old boy who immediately lost consciousness after a 17-second ECD chest shock (3). He initially had a pulse and was breathing, but two minutes after collapse had VF documented in an ECG recorded by paramedics; he was ultimately resuscitated. The accuracy of statements made in this publication was contested (4) but sworn testimony by a paramedic who witnessed the entire event (5) stated VF was recorded two minutes after the ECD shock.

The second observation was of a 17 year old man who received ECD applications of 25 and 5 seconds in the anterior chest. He immediately dropped to the ground and was observed to become cyanotic and apneic. The initial rhythm was asystole recorded more than ten minutes after the ECD application. He was eventually resuscitated using hypothermia (6) but had memory impairment.

The third publication included a 25 year old man who received ECD shocks in the anterior chest for 16, 5, and 5 seconds. He immediately lost consciousness and prompt application of an AED showed VF. After two shocks, he could not be resuscitated. The report stated that "...the time course and the electrode location are consistent with electrically induced VF." (7)

Animal and Clinical Studies

The concept of cardiac capture by transthoracic electrical impulses in humans was pioneered by Zoll et al (8), replicated by many others subsequently (9) and is now a standard part of resuscitative equipment. One hundred micro coulombs is given as the threshold for transthoracic cardiac electrical capture (10), which is the output of the TASER Model X26 (1).

Studies in pigs (11-15), sheep (16) and humans (17) established that transthoracic shocks from the TASER Model X26 or a new prototype ECD (18) caused cardiac electrical capture. In addition, porcine research showed that such electrical capture could provoke VF at normal (12-15) or higher than normal (11) TASER Model X26 outputs. Vectors encompassing the heart and probes closer to the heart facilitated electrical capture (11, 12, 15). In one study, standard 9mm probes produced VF in pigs at dart-to-heart distances of 4 to 8 mm (19). In another porcine study testing barbs at 5 locations, the authors found that 5-second shocks from the TASER X26 produced cardiac electrical capture without VF at normal outputs but that VF induction at increased output was initiated when the capture ratio was $\leq 2:1$. Bracketing the heart with darts in a sternal notch to cardiac apex position along the cardiac axis resulted in the lowest safety margin for VF induction. They stated that cardiac disease could reduce the VF threshold and provide a substrate for arrhythmia induction and that rapid ventricular capture was the likely mechanism of VF induction (20).

In addition to the importance of probe location, longer duration shocks at normal TASER X26 outputs appear more likely to induce VF (13, 14). While it is possible that body size might influence cardiac capture and development of VF, clearly “big” people can still develop VF from an ECD shock (see table).

Determining whether an ECD shock caused cardiac electrical capture can be difficult because the shock produces electrical interference in the ECG recording. In a clinical study of a new TASER ECD prototype, cardiac electrical capture monitored echocardiographically was shown to occur at 240 beats per minute (bpm) in one volunteer (18). In addition, a case report about a man with an implanted pacemaker demonstrated cardiac electrical capture at rates exceeding 200 bpm during each of two 5-second TASER Model X26 applications, that was

found when the pacemaker was interrogated (17).

Multiple clinical studies have not shown ECD-induced VF in healthy volunteers. But, because of ethical considerations, even those few studies testing actual barbs to the anterior chest and single 15-second exposures (21) may not be able to replicate the clinical scenario of a frightened/fleeing/fighting individual.

Several epidemiological studies have not shown a link between ECD shocks and sudden cardiac death (22, 23). However, a recent review (24) determined that single shocks in healthy people "... could have deleterious effects when used in the field, in particular if persons receive multiple exposures ... or present with medical comorbidities."

Proposed Mechanism of ECD Induced Sudden Cardiac Arrest



Electrical stimulation can induce VF by causing ventricular capture during the vulnerable period of the T wave of the previous beat, or ventricular capture at rates too fast for ventricular activation to remain organized. Rapid pacing also can cause a precipitous blood pressure fall, leading to ischemia. VF by rapid pacing was often the outcome of 'runaway pacemakers' many years ago (25).

It is clear from the information cited above that an ECD shock to the chest can produce cardiac electrical capture at rapid rates in animals and humans (11-18). Further, it is clear that VF has been documented as early as 2 minutes following an ECD shock to humans (3, 5). What is lacking is the actual ECG recording of VF induction *during* an ECD shock in humans, a practical impossibility unless it fortuitously occurred in an individual with a recording device already in place. Even then, electrical interference may obscure the recording. However, ECD-induced VT and VF have been clearly and repeatedly shown in pigs (11-15, 19). In one example, IV epinephrine in an anesthetized pig, infused at a concentration that increased the spontaneous

sinus rate 50% to replicate the clinical “fight or flight” situation, improved TASER Model X26 electrical capture ratio from 3:1 to 2:1 and resulted in VF induction (12).

Thus, from the pig studies, a likely clinical scenario is ECD-induced cardiac electrical capture at rates of 200-240 bpm (a 6:1 to 4:1 ratio), as already shown in humans (17, 18). The increased rate plus sympathetic effects can shorten ventricular refractoriness to permit further ECD-induced rate acceleration that eventually causes VF from the rapid rate or R on T. Because a sharp blood pressure reduction results from the rapid rate, repeated shocks or those exceeding the recommended 5-second ECD discharge can add an ischemic component and would be more likely to provoke VF. Further, based on clinical electrophysiological studies performed over many years, the presence of underlying heart disease or arrhythmogenic drugs would be expected to facilitate VF induction by electrical stimulation.

Certainly not every in-custody death occurring after ECD deployment is due to the effects of the ECD shock. Restraint asphyxia and the concept of “excited delirium” are among other explanations (26). Excited delirium may be a form of takotsubo cardiomyopathy (27). Considering the fact that extreme sympathetic stimulation likely accompanies most restraint attempts, particularly those with ECD discharge, and the relatively few reported sudden deaths, it seems more logical to conclude that the ECD rather than sympathetic stimulation was responsible for the sudden death.

Alternate explanations such as excited delirium would be more relevant when there was a significant time delay between ECD deployment and loss of consciousness/responsiveness or death (28). However, when loss of consciousness/responsiveness occurs during/immediately after an ECD chest shot, as it did in *each* of the cases above, and the subsequent rhythm is VT/VF, or asystole (if a lengthy time has elapsed without resuscitation), with no other cause

apparent, it becomes difficult to exonerate the effects of the shock. It is also possible that combinations exist. For example, prolonged QT interval in takotsubo cardiomyopathy might predispose to pacing---induced VT/VF.

Several victims were alleged to have structural heart disease (cases 2, 4, 7, and 8) and/or had elevated blood alcohol concentrations (cases 1, 3, 4, and 8). While sudden death caused by the underlying heart disease or alcohol is possible, one would have to postulate that the heart disease or alcohol coincidentally induced sudden loss of consciousness *precisely* at the time of ECD application. Far more likely is that stimulation from the ECD in the presence of structural heart disease and/or alcohol intoxication induced VT/VF. Clinical electrophysiology studies over many years have established that the presence of structural heart disease facilitates electrical induction of VT/VF, as does alcohol (29).

Institutional Reviews

A contemporary review by the National Institute of Justice concluded that the case reported as a letter to the editor (3) was ECD---induced VF, and stated that an ECD “may induce rapid ventricular pacing or VT in an individual who appears to be in satisfactory condition...lead[ing] to VF after a short delay,” and therefore “use involving the area of the chest in front of the heart area is not totally risk free.”(30). The Report of the Braidwood Commission of Inquiry (31), following an ECD-related death recorded on video in the Vancouver, British Columbia airport, stated that “There is evidence that the electrical current from a conducted energy weapon is capable of triggering ventricular capture... and that the risk of ventricular fibrillation increases as the tips of the probes get closer to the wall of the heart...[I]f a person dies suddenly and from no obvious cause after being subjected to a conducted energy weapon, death is almost certainly due to an arrhythmia.”

Incidence

Sudden death occurs infrequently following ECD deployment, considering the number of ECD applications and the apparently few reported sudden deaths. However, the actual incidence when the darts are impaled in the chest is unknown because accurate numerators and denominators are uncertain due to potential underreporting of total number of sudden deaths (numerator) and the actual number of chest shocks that might cause cardiac electrical capture (denominator). ECD applications without one or both probes in the anterior chest would not be expected to influence cardiac rhythm and likely make up a large number of the total applications (denominator) cited. Until a detailed database of ECD deployments and outcomes is created, the exact incidence will remain unknown.

Clinical Implications

It is important to stress that the purpose of this article is NOT to condemn ECD use by trained professionals. Law enforcement experts must make those decisions, not physicians. Intuitively, one would expect a “less lethal” weapon to reduce in-custody related sudden deaths and be preferable to firearms. Such may not always be the case, however. One study (32) noted that the rate of in-custody sudden deaths increased more than six-fold and the rate of firearm deaths increased more than two-fold in the first full year after ECD deployment compared with the average rate in the five years before deployment.

The main purpose of this paper is to make ECD users aware that cardiac arrest due to VF can result from an ECD shock. They should be judicious how and when to use the ECD weapon, avoid chest shocks if possible, as TASER International recommended in September, 2009, monitor the person following an ECD shock, and suspect this adverse response in any victim who loses consciousness. Users should be prepared to resuscitate, including deployment of an AED if

indicated.

Limitations

The incidence of ECD-induced sudden cardiac arrest/death cannot be determined without accurate data compiled in a national registry of ECD deployments and outcomes. Such a registry should also chart precise dart locations and be administered and reviewed by an independent oversight group.

The major limitation of this study is not having an ECG recording *during* ECD application, a practical impossibility in the field situation as noted earlier. The “hard facts” of each encounter are two events separated in time: ECD deployment and the recorded ECG. The explanation of the cause of the events in between, i.e., the loss of consciousness/responsiveness and sudden death, is based on the animal and clinical data detailed above. However, in cases 4, 6, and 8, reports stated that a pulse and/or respirations were recorded initially, which would seem to be incompatible with ECD-induced VF. Yet, the victims were totally unconscious/unresponsive directly after the ECD discharge without any other explanation, e.g., no head trauma, seizure activity, etc. While it may be possible that the sudden loss of consciousness was not due to the effects of the ECD, it is my opinion that finding a pulse (often, radial) could have been spurious during the tumultuous event and that agonal breathing could be mistaken for normal respirations. It is also possible that a pulse and respiration were present *initially* if the first rhythm was VT prior to VF, as has been found in the ECD animal studies (12). In fact, in one porcine study (13), ECD discharge induced a stable monomorphic VT that remained for about three minutes prior to degeneration to VF. An example of recording an initial pulse and respiration immediately after ECD-induced loss of consciousness was in the published NEJM letter (3) when a paramedic, present during the entire ECD deployment, felt an

initial pulse of 100 (counted for 15 seconds) and respirations of 16 (5), with VF documented electrocardiographically 2 minutes later. From these observations it is clear that *continuous* monitoring of vital signs in an individual unconscious following ECD deployment should be mandatory.

Conclusions

The animal and clinical data support the conclusion that ECD shocks from a TASER Model X26 delivered via probes to the chest can cause cardiac electrical capture. Further, if the capture rate increases sufficiently, or if R on T occurs, the development of VF, either directly or via a transition to VT, occurs in animals and, in the opinion of the author, in humans as well. How often this happens is unknown. While it would seem more likely to occur in individuals exposed to potentially arrhythmogenic drugs and/or who have structural heart disease, and following long or repeated ECD shocks, electrophysiologic studies in humans clearly show that only one or two extra stimuli can provoke VT/VF in particularly susceptible individuals.

Funding Sources: Krannert Institute of Cardiology Charitable Trust

Conflict of Interest Disclosures: The author has served (and in the future may serve) as a paid plaintiff expert witness in ECD---related sudden cardiac arrest/death cases. However, that role has provided access to critical and detailed records necessary to determine the potential for ECD-induced sudden cardiac arrest and death. Despite this conflict, the author has attempted to present the salient facts about the cases, offer scientific evidence, credible argument and logic to support the conclusions to a reasonable degree of medical certainty.

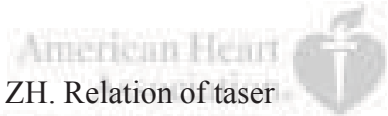
References:

1. Test results for the Model X26 conducted energy weapon (CEW) in accordance with TASER International device specifications. Report A85R9006/9031/9059B1. April 22, 2009.

2. USA: 'Less than lethal'? List of deaths following use of stun weapons in US law enforcement 3 June 2001 to 31 August 2008. Amnesty International Publications. Index Number AMR 51/010/2008. December 16, 2008.
3. Kim PJ, Franklin WH. Ventricular fibrillation after stun-gun discharge. Letter to the editor. *N Engl J Med*. 2005;353:958-959.
4. Kroll MW, Calkins H, Luceri RM. Letter to the editor. *J Amer Coll Cardiol*. 2007;49:732.
5. Hutchison J. Deposition in Circuit Court of Cook County, 21 June, 2007. Ortega-Piron v. Lopez No. 05 L 1643.
6. Schwarz ES, Barra M, Liao MM. Successful resuscitation of a patient in asystole after a TASER injury using a hypothermia protocol. *Am J Emerg Med*. 2009;27:515.e1-515.e1-2.
7. Swerdlow CD, Fishbein MC, Chaman L, Lakkireddy DR, Tchou P. Presenting rhythm in sudden deaths temporally proximate to discharge of TASER conducted electrical weapons. *Acad Emerg Med*. 2009 16:726-739.
8. Falk RH, Zoll PM, Zoll RH. Safety and efficacy of noninvasive cardiac pacing. A preliminary report. *New Engl J Med*. 1983;309:1166-1168.
9. Klein LS, Miles WM, Heger JJ, Zipes DP. Transcutaneous pacing: patient tolerance, strength-interval relations, and feasibility for programmed electrical stimulation. *Am J Cardiol*. 1988;62:1126-1129.
10. Grimnes S, Martinsen OG. Clinical applications of bioelectricity. In Biomedical engineering desk reference. Edition 1. New York. Elsevier 2009. p. 241-382.
11. Lakkireddy D, Wallick D, Ryschon K, Chung MK, Butany J, Martin JD, Saliba W, Kowalewski W, Natale A Tchou PJ. Effects of Cocaine Intoxication on the Threshold for Stun Gun Induction of Ventricular Fibrillation. *J Amer Coll Cardiol*. 2006;48:805-811.
12. Nanthakumar K, Billingsley IM, Masse S, Dorian P, Cameron D, Chauhan VS, Downar ED, Sevaptsidis E. Cardiac Electrophysiological Consequences of Neuromuscular Incapacitating Device Discharges. *J Amer Coll Cardiol*. 2006;48:798-804.
13. Dennis AJ, Valentino DJ, Walter RJ, Nagy KK, Winners J, Bokhari F, Wiley DE, Joseph KT, Roberts RR. Acute Effects of Taser X26 Discharges in a Swine Model. *J Trauma*. 2007;63:581-590.
14. Walter RJ, Dennis AJ, Valentino DJ, Margeta B, Nagy KK, Bokhari F Wiley DE, Joseph KT, Roberts RR. TASER X26 Discharges in Swine Produce Potentially Fatal Ventricular Arrhythmias. *Acad Emer Med*. 2008; 15:66-73.

15. Valentino DJ, Walter RJ, Dennis AJ, Margeta B, Starr F, MD, Nagy KK, Bokhari F, Wiley DE, Joseph KT, Roberts RR. Taser X26 Discharges in Swine: Ventricular Rhythm Capture is Dependent on Discharge Vector. *J Trauma*. 2008;65:1478-1485.
16. Dawes DM, Ho JD, Cole JB, Reardon RF, Lundin EJ, Terwey KS, Falvey DG, Miner JR. Effect of an Electronic Control Device Exposure on a methamphetamine intoxicated animal model. *Academic Emergency Medicine*. 2010; 17:436-443.
17. Cao M., Shinbane JS, Gillberg JM, Saxon LS, Swerdlow CD. Taser-induced rapid ventricular myocardial capture demonstrated by pacemaker intracardiac electrograms. *J Cardiovasc Electrophysiol*. 2008;18:876-879.
18. Ho JD, Dawes DM, Reardon RF, Strote SR, Kunz SN, Nelson RS, Lundin EJ, Orozco BS, Miner JR. Human cardiovascular effects of a new generation conducted electrical weapon. *Forensic Sci Int*. 2011;204:50-57.
19. Wu JY, Sun H, O'Rourke AP, Huebner SM, Rahko PS, Will JA, Webster JG. Taser blunt probe dart-to-heart distance causing ventricular fibrillation in pigs. *IEEE Trans Biomed Eng*. 2008;55:2768-2771.
20. Lakkireddy D, Wallick D, Verma A, Ryschon K, Kowalewski W, Wazni O, Butany J, Martin D, Tchou PJ. Cardiac effects of electrical stun guns: does position of barbs contact make a difference? *Pacing Clin Electrophysiol*. 2008;31:398-408.
21. Dawes DM, Ho JD, Johnson MA, Lundin E, Janchar TA, Miner JR. 15-Second conducted electrical weapon exposure does not cause core temperature elevation in non-environmentally stressed resting adults. *Forensic Sci Int*. 2008;176:253-257.
22. Bozeman WP, Hauda WE 2nd, Heck JJ, Graham DD, Martin BP, Winslow JE. Safety and injury profile of conducted electrical weapons used by law enforcement officers against criminal suspects. *Ann Emerg Med*. 2009;53:480-489.
23. Strote J, Walsh M, Angelidis M, Basta A, Hutson HR. Conductive electrical weapon use by law enforcement: an evaluation of safety and injury. *J Trauma*. 2010;68:1239-1246.
24. Pasquier M, Carron PM, Vallotton L, Yersin B. Electronic control device exposure: A review of morbidity and mortality. *Ann Emerg Med*. 2011;58:178-188.
25. Nasrallah A, Hall RJ, Garcia E, Kyger ER, Hallman GL, Cooley DA. Runaway pacemaker in seven patients: a persisting problem. *J Thorac Cardiovasc Surg*. 1975;69:365-368.
26. Vilke GM, DeBard ML, Chan TC, Ho JD, Dawes DM, Hall C, Curtis MD, Wysong C, Mash DC, Coffman SR, McMullen MJ, Metzger JC, Roberts JR, Sztajnkrcer MD, Henderson SO, Adler J, Czarnecki F, Heck J, Bozeman WP. Excited delirium syndrome (EXDS): Defining based on a review of the literature. *J Emer Med*. doi:10.1016/j.jemermed.2011.02.017.

27. Madias C, Fitzgibbons TP, Alsheikh-Ali AA, Bouchard JL, Kalsmith B, Garlitski AC, Tighe DA, Estes NA 3rd, Aurigemma GP, Link MS. Acquired long QT syndrome from stress cardiomyopathy is associated with ventricular arrhythmias and torsades de pointes. *Heart Rhythm*. 2011;8:555-561.
28. Ideker RE, Dossdall DJ. Can the direct cardiac effects of the electrical pulses generated by the TASER X26 cause immediate or delayed cardiac arrest in normal adults? *Am J Forensic Med Path*. 2007;28:195-201.
29. Greenspon AJ, Schaal SF. The "holiday heart": electrophysiologic studies of alcohol effects in alcoholics. *Ann Int Med*. 1983;98:135-139.
30. Study of deaths following electro muscular disruption. NIJ Report. US Department of Justice. Office of Justice Programs May, 2011.
31. Braidwood Hearing and Study Commission Report into the Death of Robert Dziekanski. 2010 (www.braidwoodinquiry.ca).
32. Lee BK, Vittinghoff E, Whiteman D, Parka M, Lau LL, Tseng ZH. Relation of taser (electrical stun gun) deployment to increase in in-custody sudden deaths. *Am J Cardiol* 2009;103:877-880.



Circulation

JOURNAL OF THE AMERICAN HEART ASSOCIATION

Table

<u>Case</u>	<u>Age</u>	<u>Height weight</u>	<u>ECD shock(s) (seconds)</u>	<u>Response to ECD shock</u>	<u>Time to initial ECG after ECD shock</u>	<u>Initial recorded rhythm</u>	<u>Drug Screen</u>	<u>Cardiac findings at autopsy</u>	<u>Comments</u>
1	48	6'0" 155 lbs	5, 8, 5	LOC toward end of last ECD cycle	Several minutes	VT/VF	BAC 0.35gm/100 ml; THC present	Survived with memory impairment; normal echocardiogram	Five AED shocks, IV epinephrine, and lidocaine eventually restored a perfusing rhythm.
2	17	5'7" 170 lbs	37, 5	LOC toward end of 37 sec cycle	>4.5 min	VF	Negative	410 gms; focal atherosclerosis; Plaintiff pathologist: normal Defense pathologist: HCM	Three defibrillating shocks, and an additional three shocks from a second AED at least nine minutes after the collapse, failed to resuscitate.
3	17	5'8" 115 lbs	5	ILOC	>5 min	VF	BAC 0.25 gm/100ml; THC present	270 gms; normal heart	Asystole developed after the AED shock and then pulseless electrical activity (PEA). Subsequently, VF recurred, a second AED shock delivered, followed by asystole/PEA and could not be resuscitated.
4	24	5'10" 176 lbs	11	ILOC	About 10 min	AED: "shockable rhythm"; asystole after shock; no recordings available.	BAC 0.319 gm/100ml	400 gms; Plaintiff pathologist: no specific pathology Defense pathologist: lymphocytic myocarditis	Said to be breathing initially with a weak radial pulse. Resuscitated in hospital; life support withdrawn after 3 days due to anoxic encephalopathy.
5	33	6'2" 220 lbs	13 shocks totaling 62 sec in <3 min	LOC toward end of multiple shocks	About 13 min	Fine VF v. asystole	Gabapentin 31µgm/ml	470 gms; 10-20% narrowing LAD; normal histology	Gabapentin taken for seizure disorder.
6	24	5'6" 144 lbs	49, 5	LOC toward end of 49 sec shock	About 10 min	VT/VF	Negative	366.7 gms; normal gross and microscopic findings	
7	16	5'3" 130 lbs	5	ILOC	About 10 min	VT/VF	THC	380 gms; Medical Examiner diagnosis: RV cardiomyopathy, disputed by plaintiff's expert	Six AED shocks for VT/VF resulted in asystole/PEA. Could not be resuscitated.
8	23	5'9" 173 lbs	21, 7, 3	LOC toward end of 21 sec shock	About 30 min	Asystole	BAC 0.111 gm/100ml	400 gms; mild interstitial fibrosis of compact AV node; interstitial fibrosis, atrophy, and vacuolization of penetrating and branching bundle	Said to be breathing with pulse, initially. Could not be resuscitated. Cardiac pathologist could not determine whether changes contributed to death

ILOC = immediate loss of consciousness during/following initial shock; lbs = pounds; gms = heart weight in grams; LAD = left anterior descending coronary artery; VT = ventricular tachycardia; VF = ventricular fibrillation; AED = automated external defibrillator; BAC = blood alcohol concentration; THC = tetrahydrocannabinol, positive screen for marijuana; gabapentin = Neurontin

Figure Legend:

Figure 1: First available ECG for 7 of the 8 cases.



